



Published in final edited form as:

Exp Eye Res. 2016 January ; 142: 19–25. doi:10.1016/j.exer.2015.03.009.

Molecular mechanisms of subretinal fibrosis in age-related macular degeneration

Keijiro Ishikawa^{1,2}, Ram Kannan¹, and David R Hinton^{2,3}

¹Arnold and Mabel Beckman Macular Research Center, Doheny Eye Institute, Los Angeles, CA, USA

²Department of Ophthalmology, Keck School of Medicine of the University of Southern California, Los Angeles, CA, USA

³Department of Pathology, Keck School of Medicine of the University of Southern California, Los Angeles, CA, USA

Abstract

Subretinal fibrosis is a result of a wound healing response that follows choroidal neovascularization in neovascular age-related macular degeneration (nAMD). Although anti-vascular endothelial growth factor therapy has become a standard treatment that improves visual acuity in many nAMD patients, unsuccessful treatment outcomes have often been attributed to the progression of subretinal fibrosis. In this review, we summarize the cellular and extracellular components of subretinal fibrous membranes and also discuss the possible molecular mechanisms including the functional involvement of growth factors and the inflammatory response in the process. Moreover, we present an murine animal model of subretinal fibrosis that might facilitate greater understanding of the pathophysiology and the development of novel therapeutic strategies for the inhibition of subretinal fibrosis in nAMD.

Keywords

extracellular matrix; epithelial-mesenchymal transition; growth factor; laser-induced choroidal neovascularization; macrophage; matricellular protein myofibroblasts; subretinal scar

1. Introduction

Neovascular age-related macular degeneration (nAMD) is a leading cause of blindness resulting from the development of choroidal neovascularization (CNV), which may progress to an end stage fibrous plaque/disciform scar (Lim et al., 2012; Ryan, 1979). Currently, anti-

Corresponding author: David R Hinton, MD, FARVO, Departments of Ophthalmology and Pathology, Keck School of Medicine of the University of Southern California, 2011 Zonal Ave. HMR 209, Los Angeles, CA 90033; Phone: (323) 442-6617; FAX: (323) 442-6688, dhinton@usc.edu.

Publisher's Disclaimer: This is a PDF file of an unedited manuscript that has been accepted for publication. As a service to our customers we are providing this early version of the manuscript. The manuscript will undergo copyediting, typesetting, and review of the resulting proof before it is published in its final citable form. Please note that during the production process errors may be discovered which could affect the content, and all legal disclaimers that apply to the journal pertain.

The authors declare no conflicts of interest.

vascular endothelial growth factor (VEGF) therapy has been the first choice for the primary treatment for CNV (Holz et al., 2014). Although anti-VEGF therapy generally stabilizes or improves visual function, subretinal scarring (fibrosis) can develop in approximately half of all treated eyes within two years after anti-VEGF treatment and has been identified as one cause of unsuccessful outcomes (Daniel et al., 2014). Subretinal fibrosis formation can cause local destruction of photoreceptors, retinal pigment epithelium (RPE), and choroidal vessels leading to permanent dysfunction of the macular visual system. Histopathologic studies of human AMD eyes suggest that the progression of photoreceptor degeneration is proportional to the diameter and thickness of the subretinal fibrosis (Green and Enger, 1993).

Fibrosis is considered an excessive wound healing response to tissue damage (Wynn, 2007). In the wound healing process, angiogenesis is initiated to aid in the repair of damaged tissue, to increase the oxygen supply, and to recruit inflammatory cells to the wounded tissue (Greaves et al., 2013). In nAMD, CNV develops in the subretinal and/or sub-pigment epithelial space, leading to hemorrhage and exudative change and culminating in subretinal fibrosis. This process is characterized by proliferation and/or infiltration of various types of cells: RPE, glial cells, fibroblasts, myofibroblast-like cells and macrophages, interacting with inflammatory cytokines and growth factors and resulting in substantial remodeling of the extracellular matrix (ECM) (Kent and Sheridan, 2003). Because of the complexity of the cellular interactions and the numerous mediators, effective therapeutic intervention for fibrosis has yet to be developed. We will review the pathophysiology associated with subretinal fibrosis and discuss the potential animal models to study this process, as well as possible therapeutic strategies for preventing fibrotic scar formation in nAMD.

2. Clinical implications

Although anti-VEGF therapy has become a standard treatment that improves visual acuity or at least prevents severe vision loss in nAMD patients with CNV, some patients have a poor response to the therapy, resulting in visual impairment despite frequent intravitreal injections of the drugs (Cohen et al., 2012). These unsuccessful outcomes have often been attributed to progression of the underlying AMD, such as the development of subretinal fibrosis, the most common natural history pattern of subfoveal CNV (Pauleikhoff, 2005). To identify the risk factors for subretinal scars, a prospective cohort study was performed in eyes of nAMD patients receiving anti-VEGF therapy (Daniel et al., 2014). It was noted that eyes with “classic” CNV lesions, which penetrate the RPE monolayer and grow in the subretinal space, are more likely to develop scar formation than those with “occult” CNV lesions, which are usually confined to the space beneath the RPE. This suggests that a subretinal lesion containing extensively damaged and scattered RPE would be more likely to progress to fibrosis; and this increased likelihood could be related to the presence of transdifferentiated RPE cells in surgically removed CNV fibrous membranes, as discussed in Section 4. Furthermore, it has been reported that fibrosis may develop after treatment with anti-VEGF drugs in nAMD and proliferative diabetic retinopathy (PDR) (Arevalo et al., 2008; Hwang et al., 2011; Van Geest et al., 2012; Barikian et al., 2015) and development of subretinal fibrosis may be associated with a bi-weekly treatment regimen in nAMD (Barikian et al., 2015). However, prompt initiation of therapy may also be beneficial for the prevention of fibrosis since development of subretinal fibrosis is associated with a longer

interval between diagnosis of nAMD and treatment with anti-VEGF drugs (Bloch et al., 2013).

In proliferative diabetic retinopathy (PDR), it has been reported that a balance between the levels of the growth factors pro-angiogenic VEGF and pro-fibrotic connective tissue growth factor (CTGF) regulates the angiogenesis to fibrosis conversion, the so-called “angio-fibrotic switch” (Kuiper et al., 2008). An increased ratio of CTGF to VEGF levels in the vitreous after anti-VEGF therapy has been suggested to be a trigger for fibrosis progression in PDR (Sohn et al., 2012; Van Geest et al., 2012). The molecular mechanism for the effect of VEGF inhibition on pro-fibrotic factors associated with subretinal fibrosis remains unclear.

3. Basic Mechanisms of Subretinal Fibrosis

Subretinal fibrosis in nAMD shares common molecular mechanisms with fibrosis in organs such as lung, liver, kidney, heart and skin (Friedlander, 2007). Generally, soon after tissue injury, epithelial cells release mediators that recruit and activate inflammatory cells, endothelial cells, and fibroblasts. In addition, the cells undergo epithelial-mesenchymal transition (EMT), which enables transdifferentiation, resulting in the conversion of epithelial cells to myofibroblasts (Kalluri and Weinberg, 2009; Wynn, 2007). The induction of neovascularization can result in the recruitment of more inflammatory cells and fibroblasts, which can be a direct or indirect source of additional myofibroblasts. Those cells produce ECM, and proliferate and migrate over the basal layers to cover and regenerate the damaged tissue; however, in the presence of repeated injury and/or chronic inflammation, the fibrotic scar will persist.

4. Cellular components of subretinal fibrous membranes

Previously, surgical removal of choroidal neovascular membranes (CNVMs) was a common treatment option for patients with nAMD. According to the histological studies of the tissues excised from those patients, CNVMs consist of connective tissues such as ECM and cellular components such as vascular endothelial cells, RPE, macrophages, myofibroblasts, pericytes and fibroblast-like cells (Grossniklaus and Green, 1998; Grossniklaus et al., 1994; Hinton et al., 1998; Lopez et al., 1996). CNVM-scars have been defined as those with an increased proportion of fibrous tissue to neovascular channels (Macular Photocoagulation Study Group, 1991). Histologic studies of human CNVMs has also demonstrated that development of fibrous scar is accompanied by an increase in apoptosis and a decrease in cellularity, suggesting that subretinal fibrosis may evolve along with regression of CNV in nAMD (Hinton et al., 1998).

In surgically excised CNV, many of the stromal cells are immunoreactive for both alpha-smooth muscle actin (α -SMA) and cytokeratin (Lopez et al., 1996). Additionally, it was observed that there was a gradient change of RPE from cytokeratin-positive, mildly α -SMA-positive cells adjacent to the normal RPE monolayer, to non-pigmented cytokeratin-positive, α -SMA-positive stromal cells, and finally to cytokeratin-negative, α -SMA-positive cells in the stroma (Lopez et al., 1996). Thus, RPE could be the origin of myofibroblastic cells through development of EMT (Grisanti and Guidry, 1995).

An additional source of α -SMA-positive cells in experimental CNV is bone marrow-derived cells. When CNV was induced in irradiated mice that had been engrafted with green fluorescent protein (GFP) positive bone marrow, many of the α -SMA-positive cells were also GFP-positive (Espinosa-Heidmann et al., 2005). Thus there is evidence to support both a local (RPE) and systemic (Bone marrow-derived cells) source for α -SMA-positive cells in CNV lesions.

4.1. Epithelial-mesenchymal transition of the RPE

In the normal eye, the RPE is a highly polarized monolayer of pigmented cells located between the neural retina and the choroid that plays a critical role in the maintenance of visual function (Strauss, 2005). Normally, the RPE retains a mature epithelial phenotype and is mitotically quiescent with cell-cell contact inhibition mediated by the homotypic adhesion of cadherins on adjacent cells (Binder et al., 2007). Once these contacts are disrupted, RPE cells lose their epithelial phenotype with decreasing expression of epithelial markers such as E-cadherin and ZO-1 and gain mesenchymal properties with increasing expression of mesenchymal markers such as N-cadherin, vimentin and α -SMA (Kalluri and Weinberg, 2009). In nAMD, RPE detachment and dissociation can occur as part of the CNV process (Ambati and Fowler, 2012). In vitro, RPE that are dissociated into single cells gain the ability to proliferate and undergo EMT (Grisanti and Guidry, 1995). It has been observed that the loss of RPE cell-cell contact induces EMT and that the initiation of proliferation coincides with a switch in cadherin isoform expression, from P- to N-cadherin. Moreover, transforming growth factor (TGF)- β , a well-established EMT-inducer in RPE cell suspensions, does not initiate EMT in differentiated RPE with well-established cell-cell contacts, suggesting that disruption of cell-cell contact is a crucial step in initiating EMT in RPE (Tamiya et al., 2010). The process of EMT can be mediated through several signaling pathways, including SMAD (Saika et al., 2004), Wnt (Chen et al., 2012) and Notch signaling (Chen et al., 2014), resulting in the up-regulation of downstream EMT-inducible transcription factors such as Snail, Slug, zinc finger E-box-binding homeobox (ZEB)1, and ZEB2 (also known as SIP1) (Hirasawa et al., 2011; Peinado et al., 2007).

4.2. Growth factors

CNVs develop in a growth factor and cytokine rich microenvironment that includes TGF- β , fibroblast growth factor (FGF), epidermal growth factor (EGF), platelet-derived growth factor (PDGF), and tumor necrosis factor- α (TNF- α). As shown in Table 1, the source of these factors may be RPE, infiltrating macrophages or fibroblasts (Kent and Sheridan, 2003; Schlingemann, 2004; Amin et al., 1994; Lopez et al., 1996; Reddy et al., 1995; Hangai et al., 2006).

These growth factors can trigger EMT in RPE (Chen et al., 2012; Bastiaans et al., 2013; Gamulescu et al., 2006; Takahashi et al., 2010) and can act on myofibroblastic cells to promote pro-fibrotic activities such as cell proliferation, migration, and ECM remodeling, through several signaling pathways: P38 Mitogen-activated protein kinase (MAPK), p44/p42 MAPK (ERK1/2), phosphatidylinositol-3 kinase (PI3K)/ Akt (protein kinase B) and SMAD (Table 1). These processes involve highly complex interactions of the above factors

and cells through coordinated interplay between their signaling networks (Greaves et al., 2013; Schultz and Wsocki, 2009).

4.3. Extracellular matrix

The most prominent ECM components in subretinal fibrosis are collagen types I and IV and fibronectin (FN), with small amounts of collagen types III, V, and VI (Das et al., 1992). Collagen type IV surrounding RPE in the stroma is also a major component of the basal membrane of normal RPE (Chen et al., 2003). In contrast, collagen type I is a newly-synthesized ECM that is responsible for maintaining the integrity of subretinal fibrous tissue (Kimoto et al., 2004).

The adhesive glycoproteins FN and laminin are ECM components that play important roles in cell migration. TGF- β and CTGF stimulate secretion of FN in RPE cells, providing a scaffold for migration of macrophages and RPE (Jin et al., 2000; Kent and Sheridan, 2003; Nagai et al., 2009). Matricellular proteins such as thrombospondin 1 (TSP1), tenascin (TNC), and osteonectin (SPARC) are present in nCNV lesions where they perform a regulatory role in the fibrotic process, binding to growth factor receptors or integrins on the cell surface and influencing the down-stream signaling associated with cell proliferation, migration, and adhesion (Kent and Sheridan, 2003). Moreover, cell-ECM binding can alter growth factor expression which can modulate both the production and degradation of the ECM (Schultz and Wsocki, 2009). TSP1 and SPARC can promote RPE migration and TSP1 can activate TGF β through integrin binding (Sheridan et al., 2002; Uchida et al., 2008). Recently, it was shown that periostin (POSTN) is produced by RPE and acts in an autocrine fashion to stimulate focal adhesion kinase (FAK) and AKT phosphorylation resulting in the promotion of cell migration, adhesion and collagen synthesis (Ishikawa et al., 2014). Furthermore, genetic ablation of POSTN inhibits experimental CNV and associated choroidal fibrosis (Nakama et al., 2015). Further studies are necessary to determine the functional interaction of ECMs and growth factors in the pathogenesis of subretinal fibrosis.

4.4. Immune response

The immune response in nAMD has been discussed mainly with respect to CNV development, such as the activation of the complement system, the promotion/suppression role of macrophages/microglia and the related inflammatory cytokines (Nussenblatt and Ferris, 2007; Patel and Chan, 2008). Although the immune responses leading to fibrosis are well defined in other organs, their involvement in subretinal fibrosis has yet to be delineated. Histopathological studies demonstrated the presence of macrophages in subretinal fibrous tissue that can potentially regulate the immune response (Lopez et al., 1996; Skeie and Mullins, 2009). Macrophages may regulate fibrosis by producing ECM including collagen 1 and FN (Gratchev et al., 2001; Vaage and Lindblad, 1990) and secreting pro-fibrotic mediators such TGF- β and PDGF that can directly activate fibroblasts (Table 1) (Wynn and Barron, 2010). In contrast, macrophages can have opposite effects, resolving and reversing fibrosis by releasing matrix metalloproteinases (MMPs) that facilitate ECM degradation (Skeie and Mullins, 2009). These diverse functional roles may be played by distinct macrophage subpopulations in CNVMs (Cao et al., 2011). Macrophages respond to Th2

cytokines, IL-4 and IL-13 and differentiate into ‘alternatively activated macrophages’ or M2 macrophages that are distinct from ‘classically activated macrophages’ or M1 macrophage. While M2 macrophages serve as pro-fibrotic effectors, releasing cytokines that act on fibroblasts and enhance ECM remodeling, Th1-inducing IL-12 increased the number of M1 macrophages, resulting in less fibrosis development in liver (Hesse et al., 2000; Wynn and Barron, 2010). The complexity of the immune response in AMD may be reflected by the limited efficacy of anti-inflammatory mediators such as steroids for the treatment of scar formation in nAMD (Ambati et al., 2013).

Recently, it has been shown that increased immunohistochemical staining for NLRP3 (NOD-, LRR- and pyrin domain-containing 3) occurs in the RPE of patients with advanced AMD where it could contribute to AMD pathogenesis through inflammasome activation (Tseng et al., 2013; Ambati et al., 2013). The recent implication of NLRP3 inflammasome activation in the pathogenesis of hepatic fibrosis (Wree et al., 2014), suggests that the inflammasome should be further evaluated for its potential role in subretinal fibrosis.

5. In vivo models

A wide range of animal models have been used to study the pathogenesis and therapy of nAMD (Grossniklaus et al., 2010); however, little has been done to develop models that specifically study subretinal fibrosis. While both large and small animal models each have their advantages and disadvantages, rodent models are particularly valuable because of the availability of a wide range of genetically manipulated lines, recombinant proteins and antibodies. In addition, quick procedure times and low animal costs are favorable compared to larger animal models (Grossniklaus et al., 2010).

5.1. Subretinal injection of peritoneal macrophages

Jo et al. (2011) describe a murine model in which macrophages are collected from peritoneal exudates induced by thioglycolate. They used laser photocoagulation to rupture Bruch membrane and injected the collected macrophages into the subretinal space. At day 7 after injection, the eyes demonstrated exacerbation of subretinal fibrosis with increased collagen deposition as well as CNV formation in the subretinal space, resembling a disciform lesion in advanced nAMD. Further, inhibitory effects of platelet-activating factor receptor antagonist, TGF- β neutralizing antibody and IL-6 receptor antibody on subretinal fibrosis could be demonstrated with use of the model (Cui et al., 2014; Zhang and Liu, 2012; Zhang et al., 2013).

One notable concern is the complexity of the model, with multiple steps, including macrophage collection, laser coagulation, and subretinal injection; such complexity may make reproducibility of the model more difficult.

5.2. Laser-induced CNV model

The original description of laser-induced subretinal neovascularization in primates showed the late progression to disciform scar in some eyes (Ryan, 1979). In recent years, the laser-induced CNV model in mice has become widely used to elucidate the pathobiology of choroidal angiogenesis and identify novel therapeutic applications (Grossniklaus et al.,

2010). Our group recently evaluated a time-dependent alteration of CNV and fibrous membrane development in the laser-induced CNV mouse model. In this model, CNV reaches a maximum on day 7, after which it starts to regress and almost completely disappears within 35 days post laser. In contrast, we observed that fibrous tissue continues to increase for up to 35 days after laser treatment (Fig. 1A). This finding is consistent with the natural clinical course of patients with nAMD in which subretinal fibrous scarring occurs subsequent to CNV. While many studies have examined the molecular mechanism of CNV in the early phase (days 3, 7 and 14), this result suggests that the mechanism of subretinal fibrosis could be studied in the late phase to specifically evaluate fibrosis-related molecular changes while lessening the influence of those associated with co-existing CNV. Interestingly, the late fibrous lesions in the laser model (Fig. 1B) resemble optical coherence tomography images taken from AMD patients with subretinal fibrosis (Fig. 1C) (Daniel et al., 2014). The subretinal fibrosis lesions in these mice contain RPE that are transdifferentiated into myofibroblasts (Fig. 2), which is consistent with the finding of myofibroblastic RPE in human subretinal fibrous membranes excised from patients with nAMD (Lopez et al., 1996). Therefore we propose that the late phase of the laser-induced CNV model may be useful for studying the pathophysiology of subretinal fibrosis.

6. Potential therapeutic targets

Therapeutic strategies for the prevention of inhibition of subretinal fibrosis are currently an active area of investigation. It has been suggested that early anti-VEGF treatment intervention for nAMD may prevent development of subretinal fibrosis (Bloch et al., 2013). In primate and murine models, VEGF inhibition by intravenous injection of nanoparticles delivering plasmids containing Flt23k intraceptors suppressed both CNV and subretinal fibrosis (Luo et al., 2013).

Sphingosine-1-phosphate (S1P), a low molecular weight sphingolipid signaling growth factor, has been suggested as a target molecule for the treatment of subretinal fibrosis (Caballero et al., 2009). S1P is a pro-fibrotic molecule that activates multiple non-ocular fibroblast lineages and that interacts with pro-fibrotic mediators such as PDGF, TGF β and CTGF. A monoclonal antibody against S1P suppresses subretinal fibrosis as shown by a reduction in collagen deposition in the late phase after laser injury in mice.

Many of the critical players in subretinal fibrosis are likely to be the growth factors and the matricellular proteins that are involved in EMT and the fibrotic process, including cell proliferation, migration and ECM remodeling. Among these, PDGF is known to have a pro-angiogenic role in stabilizing vessels by supporting pericyte-endothelial interactions (Abramsson et al., 2003). A preclinical study has shown that combined inhibition of VEGF and PDGF is more effective than inhibition of VEGF alone in regressing CNV in a mouse model (Jo et al., 2006). Another approach for inhibition of both VEGF and PDGF is through regulation of gene expression by microRNAs (He et al., 2013). Currently, several clinical trials for the treatment for nAMD have been evaluating the efficacy of dual VEGF/PDGF inhibitors [E10030 (Ophthotech), an anti-PDGF pegylated aptamer as an adjunct to anti-VEGF therapy; Sorafenib, an inhibitor of VEGF receptor (VEGFR), PDGF receptor (PDGFR) and Raf kinases; Pazopanib, an inhibitor of VEGFR, PDGFR and c-kit (Kudelka

et al., 2013)]. In addition to the additive effect on CNV suppression, the dual blockade of VEGF/PDGF has the potential to be more beneficial than VEGF inhibition alone because PDGF inhibition has the theoretical benefit of reducing subretinal fibrosis following CNV regression. The clinical efficacies of these drugs on subretinal fibrosis have yet to be evaluated.

7. Conclusion

Development of subretinal fibrosis in nAMD has been attracting the interest of both clinicians and basic scientists since it can influence the successful outcome of therapy for nAMD. Nevertheless, the molecular pathogenesis remains unclear. In this review, we discuss the role of the cellular and ECM constituents of the fibrotic lesion, as well as the importance of growth factor mediated EMT in the RPE and the complex signaling networks that are involved. Finally, we propose the utility of the laser-induced CNV model as a subretinal fibrosis model, which might help establish a evaluate novel therapeutic approaches to reduce subretinal scar formation and prevent vision loss in nAMD.

Acknowledgements

This work was supported by National Institutes of Health Grants EY03040, EY01545 and the Arnold and Mabel Beckman Foundation and Research. K. Ishikawa is supported by a fellowship from the Japan Society for the Promotion of Science Postdoctoral Fellowships for Research Abroad. We thank Ernesto Barron and Christine Spee for technical assistance.

Abbreviations

α-SMA	alpha-smooth muscle actin
BM	bone marrow
CNV	choroidal neovascularization
CNVMs	choroidal neovascular membranes
CTGF	connective tissue growth factor
ECM	extracellular matrix
EGF	epidermal growth factor
EMT	epithelial-mesenchymal transition
FAK	focal adhesion kinase
FGF	fibroblast growth factor
FN	fibronectin
MAPK	mitogen-activated protein kinase
MMPs	matrix metalloproteinase
nAMD	neovascular age-related macular degeneration
PDGF	platelet derived growth factor

PDR	proliferative diabetic retinopathy
PI3K	phosphatidylinositol-3 kinase
POSTN	periostin
PVR	proliferative vitreoretinopathy
RPE	retinal pigment epithelium
S1P	sphingosine-1-phosphate
SPARC	osteonectin
TGF-β	transforming growth factor- β
TNC	tenascin
TNF-α	tumor necrosis factor- α
TSP1	thrombospondin 1
VEGF	vascular endothelial growth factor
ZEB	zinc finger E-box-binding homeobox
ZO-1	zonula occludens protein-1

References

- Abramsson A, Lindblom P, Betsholtz C. Endothelial and nonendothelial sources of PDGF-B regulate pericyte recruitment and influence vascular pattern formation in tumors. *J Clin Invest*. 2003; 112:1142–1151. [PubMed: 14561699]
- Ambati J, Atkinson JP, Gelfand BD. Immunology of age-related macular degeneration. *Nature reviews. Immunology*. 2013; 13:438–451. [PubMed: 23702979]
- Ambati J, Fowler BJ. Mechanisms of age-related macular degeneration. *Neuron*. 2012; 75:26–39. [PubMed: 22794258]
- Amin R, Puklin JE, Frank RN. Growth factor localization in choroidal neovascular membranes of age-related macular degeneration. *Invest Ophthalmol Vis Sci*. 1994; 35:3178–3188. [PubMed: 7519180]
- Arevalo JF, Maia M, Flynn HW Jr, Saravia M, Avery RL, Wu L, Eid Farah M, Pieramici DJ, Berrocal MH, Sanchez JG. Tractional retinal detachment following intravitreal bevacizumab (Avastin) in patients with severe proliferative diabetic retinopathy. *Br J Ophthalmol*. 2008; 92:213–216. [PubMed: 17965108]
- Barikian A, Mahfoud Z, Abdulaal M, Safar A, Bashshur ZF. Induction with intravitreal bevacizumab every two weeks in the management of neovascular age-related macular degeneration. *Am J Ophthalmol*. 2015; 159:131–137. [PubMed: 25308787]
- Bastiaans J, van Meurs JC, van Holten-Neelen C, Nagtzaam NM, van Hagen PM, Chambers RC, Hooijkaas H, Dik WA. Thrombin induces epithelial-mesenchymal transition and collagen production by retinal pigment epithelial cells via autocrine PDGF-receptor signaling. *Invest Ophthalmol Vis Sci*. 2013; 54:8306–8314. [PubMed: 24302586]
- Binder S, Stanzel BV, Krebs I, Glittenberg C. Transplantation of the RPE in AMD. *Prog Retin Eye Res*. 2007; 26:516–554. [PubMed: 17532250]
- Bloch SB, Lund-Andersen H, Sander B, Larsen M. Subfoveal fibrosis in eyes with neovascular age-related macular degeneration treated with intravitreal ranibizumab. *Am J Ophthalmol*. 2013; 156:116–124. e111. [PubMed: 23664150]
- Caballero S, Swaney J, Moreno K, Afzal A, Kielczewski J, Stoller G, Cavalli A, Garland W, Hansen G, Sabbadini R, Grant MB. Anti-sphingosine-1-phosphate monoclonal antibodies inhibit

- angiogenesis and sub-retinal fibrosis in a murine model of laser-induced choroidal neovascularization. *Exp Eye Res.* 2009; 88:367–377. [PubMed: 18723015]
- Cao X, Shen D, Patel MM, Tuo J, Johnson TM, Olsen TW, Chan CC. Macrophage polarization in the maculae of age-related macular degeneration: a pilot study. *Pathology international.* 2011; 61:528–535. [PubMed: 21884302]
- Chen HC, Zhu YT, Chen SY, Tseng SC. Wnt signaling induces epithelial-mesenchymal transition with proliferation in ARPE-19 cells upon loss of contact inhibition. *Lab Invest.* 2012; 92:676–687. [PubMed: 22391957]
- Chen L, Miyamura N, Ninomiya Y, Handa JT. Distribution of the collagen IV isoforms in human Bruch's membrane. *Br J Ophthalmol.* 2003; 87:212–215. [PubMed: 12543754]
- Chen X, Xiao W, Liu X, Zeng M, Luo L, Wu M, Ye S, Liu Y. Blockade of Jagged/Notch pathway abrogates transforming growth factor beta2-induced epithelial-mesenchymal transition in human retinal pigment epithelium cells. *Current molecular medicine.* 2014; 14:523–534. [PubMed: 24694299]
- Chen YJ, Tsai RK, Wu WC, He MS, Kao YH, Wu WS. Enhanced PKCdelta and ERK signaling mediate cell migration of retinal pigment epithelial cells synergistically induced by HGF and EGF. *PLoS ONE.* 2012; 7:e44937. [PubMed: 23028692]
- Cohen SY, Oubraham H, Uzzan J, Dubois L, Tadayoni R. Causes of unsuccessful ranibizumab treatment in exudative age-related macular degeneration in clinical settings. *Retina.* 2012; 32:1480–1485. [PubMed: 22258164]
- Cui W, Zhang H, Liu ZL. Interleukin-6 receptor blockade suppresses subretinal fibrosis in a mouse model. *International journal of ophthalmology.* 2014; 7:194–197. [PubMed: 24790857]
- Daniel E, Toth CA, Grunwald JE, Jaffe GJ, Martin DF, Fine SL, Huang J, Ying GS, Hagstrom SA, Winter K, Maguire MG. Risk of scar in the comparison of age-related macular degeneration treatments trials. *Ophthalmology.* 2014; 121:656–666. [PubMed: 24314839]
- Das A, Puklin JE, Frank RN, Zhang NL. Ultrastructural immunocytochemistry of subretinal neovascular membranes in age-related macular degeneration. *Ophthalmology.* 1992; 99:1368–1376. [PubMed: 1407971]
- Defoe DM, Grindstaff RD. Epidermal growth factor stimulation of RPE cell survival: contribution of phosphatidylinositol 3-kinase and mitogen-activated protein kinase pathways. *Exp Eye Res.* 2004; 79:51–59. [PubMed: 15183100]
- Espinosa-Heidmann DG, Reinoso MA, Pina Y, Csaky KG, Caicedo A, Cousins SW. Quantitative enumeration of vascular smooth muscle cells and endothelial cells derived from bone marrow precursors in experimental choroidal neovascularization. *Exp Eye Res.* 2005; 80:369–378. [PubMed: 15721619]
- Friedlander M. Fibrosis and diseases of the eye. *J Clin Invest.* 2007; 117:576–586. [PubMed: 17332885]
- Galy A, Neron B, Planque N, Saule S, Eychene A. Activated MAPK/ERK kinase (MEK-1) induces transdifferentiation of pigmented epithelium into neural retina. *Dev Biol.* 2002; 248:251–264. [PubMed: 12167402]
- Gamulescu MA, Chen Y, He S, Spee C, Jin M, Ryan SJ, Hinton DR. Transforming growth factor beta2-induced myofibroblastic differentiation of human retinal pigment epithelial cells: regulation by extracellular matrix proteins and hepatocyte growth factor. *Exp Eye Res.* 2006; 83:212–222. [PubMed: 16563380]
- Gratchev A, Guillot P, Hakiy N, Politz O, Orfanos CE, Schledzewski K, Goerdt S. Alternatively activated macrophages differentially express fibronectin and its splice variants and the extracellular matrix protein betaIG-H3. *Scandinavian journal of immunology.* 2001; 53:386–392. [PubMed: 11285119]
- Greaves NS, Ashcroft KJ, Baguneid M, Bayat A. Current understanding of molecular and cellular mechanisms in fibroplasia and angiogenesis during acute wound healing. *Journal of dermatological science.* 2013; 72:206–217. [PubMed: 23958517]
- Green WR, Enger C. Age-related macular degeneration histopathologic studies. The 1992 Lorenz E. Zimmerman Lecture. *Ophthalmology.* 1993; 100:1519–1535. [PubMed: 7692366]

- Grisanti S, Guidry C. Transdifferentiation of retinal pigment epithelial cells from epithelial to mesenchymal phenotype. *Invest Ophthalmol Vis Sci.* 1995; 36:391–405. [PubMed: 7531185]
- Grossniklaus HE, Green WR. Histopathologic and ultrastructural findings of surgically excised choroidal neovascularization. Submacular Surgery Trials Research Group. *Arch Ophthalmol.* 1998; 116:745–749. [PubMed: 9639442]
- Grossniklaus HE, Hutchinson AK, Capone A Jr, Woolfson J, Lambert HM. Clinicopathologic features of surgically excised choroidal neovascular membranes. *Ophthalmology.* 1994; 101:1099–1111. [PubMed: 7516516]
- Grossniklaus HE, Kang SJ, Berglin L. Animal models of choroidal and retinal neovascularization. *Prog Retin Eye Res.* 2010; 29:500–519. [PubMed: 20488255]
- Hangai M, He S, Hoffmann S, Lim JI, Ryan SJ, Hinton DR. Sequential induction of angiogenic growth factors by TNF-alpha in choroidal endothelial cells. *J Neuroimmunol.* 2006; 171:45–56. [PubMed: 16288810]
- He S, Chen Y, Khankan R, Barron E, Burton R, Zhu D, Ryan SJ, Oliver N, Hinton DR. Connective tissue growth factor as a mediator of intraocular fibrosis. *Invest Ophthalmol Vis Sci.* 2008; 49:4078–4088. [PubMed: 18450591]
- He S, Li X, Chan N, Hinton DR. Review: Epigenetic mechanisms in ocular disease. *Mol Vis.* 2013; 19:665–674. [PubMed: 23559860]
- Hecquet C, Lefevre G, Valtink M, Engelmann K, Mascarelli F. Activation and role of MAP kinase-dependent pathways in retinal pigment epithelial cells: ERK and RPE cell proliferation. *Invest Ophthalmol Vis Sci.* 2002; 43:3091–3098. [PubMed: 12202534]
- Hesse M, Cheever AW, Jankovic D, Wynn TA. NOS-2 mediates the protective anti-inflammatory and antifibrotic effects of the Th1-inducing adjuvant, IL-12, in a Th2 model of granulomatous disease. *Am J Pathol.* 2000; 157:945–955. [PubMed: 10980133]
- Hinton DR, He S, Lopez PF. Apoptosis in surgically excised choroidal neovascular membranes in age-related macular degeneration. *Arch Ophthalmol.* 1998; 116:203–209. [PubMed: 9488273]
- Hirasawa M, Noda K, Noda S, Suzuki M, Ozawa Y, Shinoda K, Inoue M, Ogawa Y, Tsubota K, Ishida S. Transcriptional factors associated with epithelial-mesenchymal transition in choroidal neovascularization. *Mol Vis.* 2011; 17:1222–1230. [PubMed: 21617757]
- Holz FG, Schmitz-Valckenberg S, Fleckenstein M. Recent developments in the treatment of age-related macular degeneration. *J Clin Invest.* 2014; 124:1430–1438. [PubMed: 24691477]
- Hwang JC, Del Priore LV, Freund KB, Chang S, Iranmanesh R. Development of subretinal fibrosis after anti-VEGF treatment in neovascular age-related macular degeneration. *Ophthalmic Surg Lasers Imaging.* 2011; 42:6–11. [PubMed: 20954648]
- Ishikawa K, Yoshida S, Nakao S, Nakama T, Kita T, Asato R, Sassa Y, Arita R, Miyazaki M, Enaida H, Oshima Y, Murakami N, Niuro H, Ono J, Matsuda A, Goto Y, Akashi K, Izuhara K, Kudo A, Kono T, Hafezi-Moghadam A, Ishibashi T. Periostin promotes the generation of fibrous membranes in proliferative vitreoretinopathy. *Faseb J.* 2014; 28:131–142. [PubMed: 24022401]
- Jin M, He S, Worpel V, Ryan SJ, Hinton DR. Promotion of adhesion and migration of RPE cells to provisional extracellular matrices by TNF-alpha. *Invest Ophthalmol Vis Sci.* 2000; 41:4324–4332. [PubMed: 11095634]
- Jo N, Mailhos C, Ju M, Cheung E, Bradley J, Nishijima K, Robinson GS, Adamis AP, Shima DT. Inhibition of platelet-derived growth factor B signaling enhances the efficacy of anti-vascular endothelial growth factor therapy in multiple models of ocular neovascularization. *Am J Pathol.* 2006; 168:2036–2053. [PubMed: 16723717]
- Jo YJ, Sonoda KH, Oshima Y, Takeda A, Kohno R, Yamada J, Hamuro J, Yang Y, Notomi S, Hisatomi T, Ishibashi T. Establishment of a new animal model of focal subretinal fibrosis that resembles disciform lesion in advanced age-related macular degeneration. *Invest Ophthalmol Vis Sci.* 2011; 52:6089–6095. [PubMed: 21051730]
- Kalluri R, Weinberg RA. The basics of epithelial-mesenchymal transition. *J Clin Invest.* 2009; 119:1420–1428. [PubMed: 19487818]
- Kent D, Sheridan C. Choroidal neovascularization: a wound healing perspective. *Mol Vis.* 2003; 9:747–755. [PubMed: 14735062]

- Kimoto K, Nakatsuka K, Matsuo N, Yoshioka H. p38 MAPK mediates the expression of type I collagen induced by TGF-beta 2 in human retinal pigment epithelial cells ARPE-19. *Invest Ophthalmol Vis Sci.* 2004; 45:2431–2437. [PubMed: 15223827]
- Kudelka M, Grossniklaus H, Mandell K. Emergence of dual VEGF and PDGF antagonists in the treatment of exudative age-related macular degeneration. *Expert Review of Ophthalmology.* 2013; 8(5):475–448.
- Kuiper EJ, Van Nieuwenhoven FA, de Smet MD, van Meurs JC, Tanck MW, Oliver N, Klaassen I, Van Noorden CJ, Goldschmeding R, Schlingemann RO. The angio-fibrotic switch of VEGF and CTGF in proliferative diabetic retinopathy. *PLoS ONE.* 2008; 3:e2675. [PubMed: 18628999]
- Lim LS, Mitchell P, Seddon JM, Holz FG, Wong TY. Age-related macular degeneration. *Lancet.* 2012; 379:1728–1738. [PubMed: 22559899]
- Lopez PF, Sippy BD, Lambert HM, Thach AB, Hinton DR. Transdifferentiated retinal pigment epithelial cells are immunoreactive for vascular endothelial growth factor in surgically excised age-related macular degeneration-related choroidal neovascular membranes. *Invest Ophthalmol Vis Sci.* 1996; 37:855–868. [PubMed: 8603870]
- Luo L, Zhang X, Hirano Y, Tyagi P, Barabas P, Uehara H, Miya TR, Singh N, Archer B, Qazi Y, Jackman K, Das SK, Olsen T, Chennamaneni SR, Stagg BC, Ahmed F, Emerson L, Zygmunt K, Whitaker R, Mamalis C, Huang W, Gao G, Srinivas SP, Krizaj D, Baffi J, Ambati J, Kompella UB, Ambati BK. Targeted intraceptor nanoparticle therapy reduces angiogenesis and fibrosis in primate and murine macular degeneration. *ACS nano.* 2013; 7:3264–3275. [PubMed: 23464925]
- Macular Photocoagulation Study Group. Subfoveal neovascular lesions in age-related macular degeneration. Guidelines for evaluation and treatment in the macular photocoagulation study. *Arch Ophthalmol.* 1991; 109:1242–1257. [PubMed: 1718252]
- Nagai N, Klimava A, Lee WH, Izumi-Nagai K, Handa JT. CTGF is increased in basal deposits and regulates matrix production through the ERK (p42/p44mapk) MAPK and the p38 MAPK signaling pathways. *Invest Ophthalmol Vis Sci.* 2009; 50:1903–1910. [PubMed: 19011018]
- Nakama T, Yishida S, Ishikawa K, Kobayashi Y, Zhou Y, Nakao S, Sassa Y, Oshima Y, Takao K, Shimahara A, Yoshikawa K, Hamasaki T, Ohgi T, Hayashi H, Matsuda A, Kudo A, Nozaki M, Ogura Y, Kuroda M, Ishibashi T. Inhibition of choroidal fibrovascular membrane formation by a new class of RNA interference therapeutic agent targeting periostin. *Gene Ther.* 2015; 22:127–137. [PubMed: 25503692]
- Nussenblatt RB, Ferris F 3rd. Age-related macular degeneration and the immune response: implications for therapy. *Am J Ophthalmol.* 2007; 144:618–626. [PubMed: 17698021]
- Patel M, Chan CC. Immunopathological aspects of age-related macular degeneration. *Semin Immunopathol.* 2008; 30:97–110. [PubMed: 18299834]
- Pauleikhoff D. Neovascular age-related macular degeneration: Natural History and Treatment Outcomes. *Retina.* 2005; 25:1065–1084. [PubMed: 16340538]
- Peinado H, Olmeda D, Cano A. Snail, Zeb and bHLH factors in tumour progression: an alliance against the epithelial phenotype? *Nature reviews. Cancer.* 2007; 7:415–428. [PubMed: 17508028]
- Reddy VM, Zamora RL, Kaplan HJ. Distribution of growth factors in subfoveal neovascular membranes in age-related macular degeneration and presumed ocular histoplasmosis syndrome. *Am J Ophthalmol.* 1995; 120:291–301. [PubMed: 7661200]
- Rosenkranz S, DeMali KA, Gelderloos JA, Bazenet C, Kazlauskas A. Identification of the 23 receptor-associated signaling enzymes that are required for platelet-derived growth factor-AA-dependent chemotaxis and DNA synthesis. *J Biol Chem.* 1999; 274:28335–28343. [PubMed: 10497192]
- Ryan SJ. The development of an experimental model of subretinal neovascularization in disciform macular degeneration. *Transactions of the American Ophthalmological Society.* 1979; 77:707–745. [PubMed: 94717]
- Saika S, Kono-Saika S, Tanaka T, Yamanaka O, Ohnishi Y, Sato M, Muragaki Y, Ooshima A, Yoo J, Flanders KC, Roberts AB. Smad3 is required for dedifferentiation of retinal pigment epithelium following retinal detachment in mice. *Lab Invest.* 2004; 84:1245–1258. [PubMed: 15273699]
- Saika S, Yamanaka O, Ikeda K, Kim-Mitsuyama S, Flanders KC, Yoo J, Roberts AB, Nishikawa-Ishida I, Ohnishi Y, Muragaki Y, Ooshima A. Inhibition of p38MAP kinase suppresses fibrotic reaction of retinal pigment epithelial cells. *Lab Invest.* 2005; 85:838–850. [PubMed: 15924151]

- Schlingemann RO. Role of growth factors and the wound healing response in age-related macular degeneration. *Graefes Arch Clin Exp Ophthalmol*. 2004; 242:91–101. [PubMed: 14685874]
- Schultz GS, Wysocki A. Interactions between extracellular matrix and growth factors in wound healing. *Wound repair and regeneration : official publication of the Wound Healing Society [and] the European Tissue Repair Society*. 2009; 17:153–162.
- Sheridan CM, Magee RM, Hiscott PS, Hagan S, Wong DH, McGalliard JN, Grierson I. The role of matricellular proteins thrombospondin-1 and osteonectin during RPE cell migration in proliferative vitreoretinopathy. *Curr Eye Res*. 2002; 25:279–285. [PubMed: 12658547]
- Skeie JM, Mullins RF. Macrophages in neovascular age-related macular degeneration: friends or foes? *Eye (Lond)*. 2009; 23:747–755. [PubMed: 18600240]
- Sohn EH, He S, Kim LA, Salehi-Had H, Javaheri M, Spee C, Dustin L, Hinton DR, Elliott D. Angiofibrotic response to vascular endothelial growth factor inhibition in diabetic retinal detachment: report no. 1. *Arch Ophthalmol*. 2012; 130:1127–1134. [PubMed: 22965588]
- Spraul CW, Kaven C, Lang GK, Lang GE. Effect of growth factors on bovine retinal pigment epithelial cell migration and proliferation. *Ophthalmic Res*. 2004; 36:166–171. [PubMed: 15103208]
- Strauss O. The retinal pigment epithelium in visual function. *Physiological reviews*. 2005; 85:845–881. [PubMed: 15987797]
- Takahashi E, Nagano O, Ishimoto T, Yae T, Suzuki Y, Shinoda T, Nakamura S, Niwa S, Ikeda S, Koga H, Tanihara H, Saya H. Tumor necrosis factor-alpha regulates transforming growth factor-beta-dependent epithelial-mesenchymal transition by promoting hyaluronan-CD44-moesin interaction. *J Biol Chem*. 2010; 285:4060–4073. [PubMed: 19965872]
- Tamiya S, Liu L, Kaplan HJ. Epithelial-mesenchymal transition and proliferation of retinal pigment epithelial cells initiated upon loss of cell-cell contact. *Invest Ophthalmol Vis Sci*. 2010; 51:2755–2763. [PubMed: 20042656]
- Tseng WA, Thein T, Kinnunen K, Lashkari K, Gregory MS, D'Amore PA, Ksander BR. NLRP3 inflammasome activation in retinal pigment epithelial cells by lysosomal destabilization: implications for age-related macular degeneration. *Invest Ophthalmol Vis Sci*. 2013; 54:110–120. [PubMed: 23221073]
- Uchida H, Kuroki M, Shitama T, Hayashi H. Activation of TGF-beta1 through up-regulation of TSP-1 by retinoic acid in retinal pigment epithelial cells. *Curr Eye Res*. 2008; 33:199–203. [PubMed: 18293192]
- Vaage J, Lindblad WJ. Production of collagen type I by mouse peritoneal macrophages. *J Leukoc Biol*. 1990; 48:274–280. [PubMed: 2202772]
- Van Geest RJ, Lesnik-Oberstein SY, Tan HS, Mura M, Goldschmeding R, Van Noorden CJ, Klaassen I, Schlingemann RO. A shift in the balance of vascular endothelial growth factor and connective tissue growth factor by bevacizumab causes the angiofibrotic switch in proliferative diabetic retinopathy. *Br J Ophthalmol*. 2012; 96:587–590. [PubMed: 22289291]
- Wree A, McGeough MD, Pena CA, Schlattjan M, Li H, Inzaugarat ME, Messer K, Canbay A, Hoffman HM, Feldstein AE. NLRP3 inflammasome activation is required for fibrosis development in NAFLD. *J Mol Med (Berl)*. 2014; 92:1069–1082. [PubMed: 24861026]
- Wynn TA. Common and unique mechanisms regulate fibrosis in various fibroproliferative diseases. *J Clin Invest*. 2007; 117:524–529. [PubMed: 17332879]
- Wynn TA, Barron L. Macrophages: master regulators of inflammation and fibrosis. *Seminars in liver disease*. 2010; 30:245–257. [PubMed: 20665377]
- Yang Y, Takeda A, Yoshimura T, Oshima Y, Sonoda KH, Ishibashi T. IL-10 is significantly involved in HSP70-regulation of experimental subretinal fibrosis. *PLoS ONE*. 2013; 8:e80288. [PubMed: 24376495]
- Zhang H, Liu ZL. Transforming growth factor-beta neutralizing antibodies inhibit subretinal fibrosis in a mouse model. *International journal of ophthalmology*. 2012; 5:307–311. [PubMed: 22773978]
- Zhang H, Yang Y, Takeda A, Yoshimura T, Oshima Y, Sonoda KH, Ishibashi T. A Novel Platelet-Activating Factor Receptor Antagonist Inhibits Choroidal Neovascularization and Subretinal Fibrosis. *PLoS ONE*. 2013; 8:e68173. [PubMed: 23826375]

Highlights

- Clinical implications of subretinal fibrosis in AMD
- Cellular and extracellular components of subretinal fibrous membranes
- Growth factors and epithelial mesenchymal transition in subretinal fibrosis
- Immune response related to subretinal fibrosis.
- Use of the laser-induced murine model of CNV to study subretinal fibrosis.

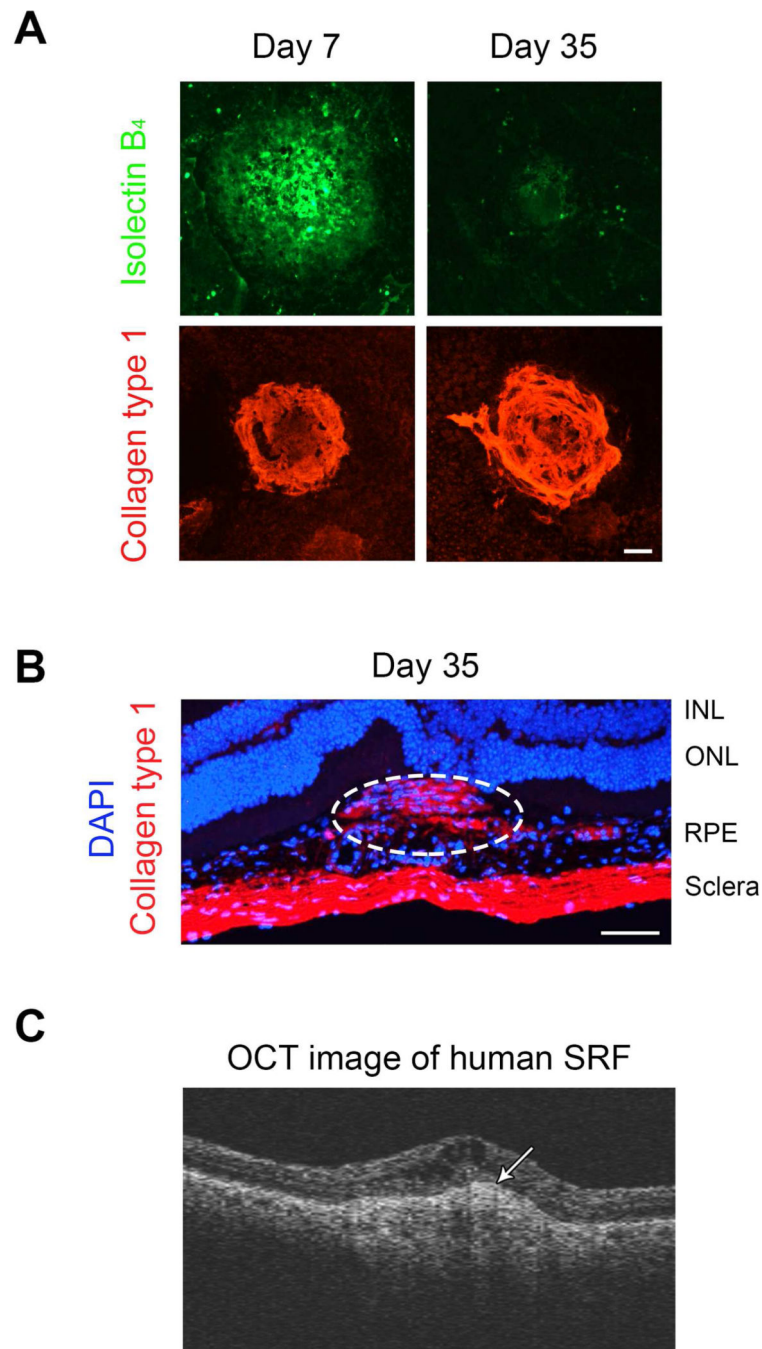


Figure 1.

Induction of subretinal fibrosis in laser-induced CNV.

A. The choroidal flat mounts were stained with antibodies against isolectin B₄ (green) and collagen type I (red) to represent neovascular and fibrous tissue respectively in mice on days 7 and 35 after laser treatment. CNV lesion size markedly decreased from day 7 to day 35, while the lesion size of fibrous tissue was larger on day 35 as compared to day 7. Scale bar = 100 μ m.

B. Histologic section through a CNV membrane at day 35 post laser. Fibrous tissue is shown by immunoreactivity to collagen 1 (red; dotted circle) and can be seen in the subretinal space. ONL= outer nuclear layer; INL=inner nuclear layer. Scale bar = 100 μ m.

C. Optical coherence tomography (OCT) image obtained from a nAMD patient with subretinal fibrosis (SRF). Fig.C reprinted from *Ophthalmology*, Volume 121, Daniel, E., Toth, C.A., Grunwald, J.E., Jaffe, G.J., Martin, D.F., Fine, S.L., Huang, J., Ying, G.S., Hagstrom, S.A., Winter, K., Maguire, M.G., Risk of scar in the comparison of age-related treatment trials, Pages 656–666, with permission from Elsevier.

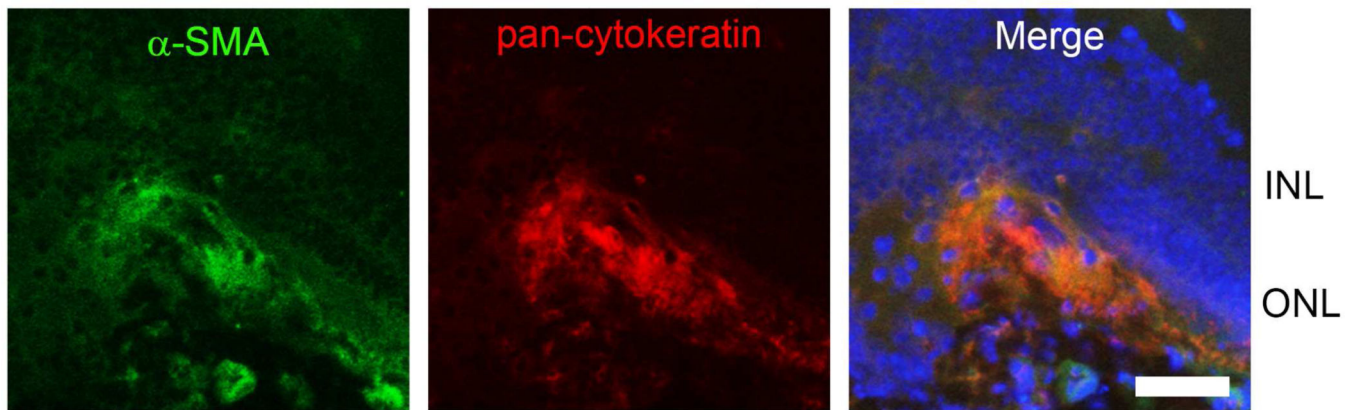


Figure 2. Immunofluorescence staining for α -SMA (α -smooth muscle actin, a marker for myofibroblasts; red) and pan-cytokeratin (a marker for RPE; blue) in the subretinal fibrosis lesion at day 35 post laser-induced Bruch membrane rupture in the mouse. Nuclei are counterstained with DAPI (blue). ONL= outer nuclear layer; INL=inner nuclear layer. Scale bar: 50 μ m.

Table 1

Growth factors and their functional roles.

Growth factors	Primary Sources	Roles	Signaling Pathway	References
TGF- β	RPE, macrophage, fibroblasts	Adhesion, ECM deposition, Migration	SMAD, P38 MAPK	(Amin et al., 1994; Lopez et al., 1996; Reddy et al., 1995); (Kent and Sheridan, 2003; Saika et al., 2004, 2005)
PDGF	RPE, macrophage, fibroblast	ECM deposition, Migration, Proliferation	ERK1/2, PI3K/AKT	(Kent and Sheridan, 2003; Schlingemann, 2004)(Spraul et al., 2004)(Hecquet et al., 2002; Rosenkranz et al., 1999)
FGF	RPE, macrophage	Migration, Proliferation	ERK1/2, P38MAPK	(Amin et al., 1994); (Galy et al., 2002; Kent and Sheridan, 2003; Spraul et al., 2004)
EGF	macrophage	Migration, Proliferation	ERK1/2, PI3K/AKT	(Kent and Sheridan, 2003; Spraul et al., 2004) (Chen et al., 2012)(Defoe and Grindstaff, 2004)
TNF- α	macrophage	Adhesion, Migration	ERK1/2	(Hangai et al., 2006) (Jin et al., 2000)
CTGF	RPE, fibroblasts	ECM deposition, Migration	ERK1/2, P38MAPK	(He et al., 2008; Nagai et al., 2009)

Abbreviations: CTGF, connective tissue growth factor; ECM, extracellular matrix; EGF, epidermal growth factor; FGF, fibroblast growth factor; MAPK, mitogen-activated protein kinase; PDGF, platelet derived growth factor; PI3K, phosphatidylinositol-3 kinase; RPE, retinal pigment epithelium; TGF- β , transforming growth factor- β ; TNF- α , tumor necrosis factor- α .